

eLearning
by **Dr. M.G.R** EDUCATIONAL AND RESEARCH INSTITUTE



Dr. M.G.R

EDUCATIONAL AND RESEARCH INSTITUTE

(Deemed to be University with Graded Autonomy Status)

Accredited by NAAC with 'A' Grade | An ISO Certified Institution

Maduravoyal, Chennai - 600 095, Tamilnadu, INDIA

Copyrights
Reserved by





Department
Topic

- Periodontology
- Resective Osseous
Surgery

Staff name

- Dr. Archana. B



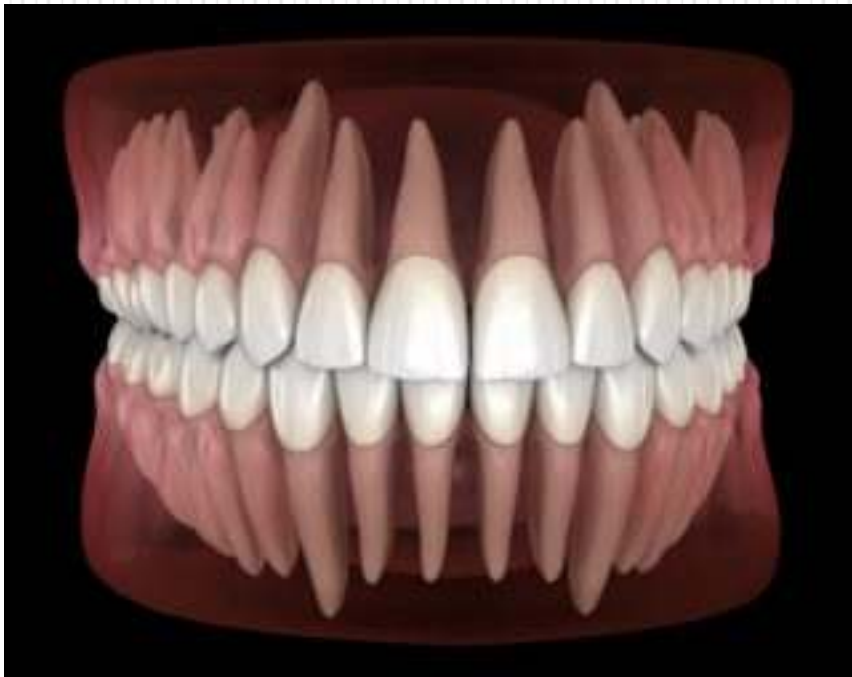Dr. M.G.R.
EDUCATIONAL AND RESEARCH INSTITUTE
(Deemed to be University)

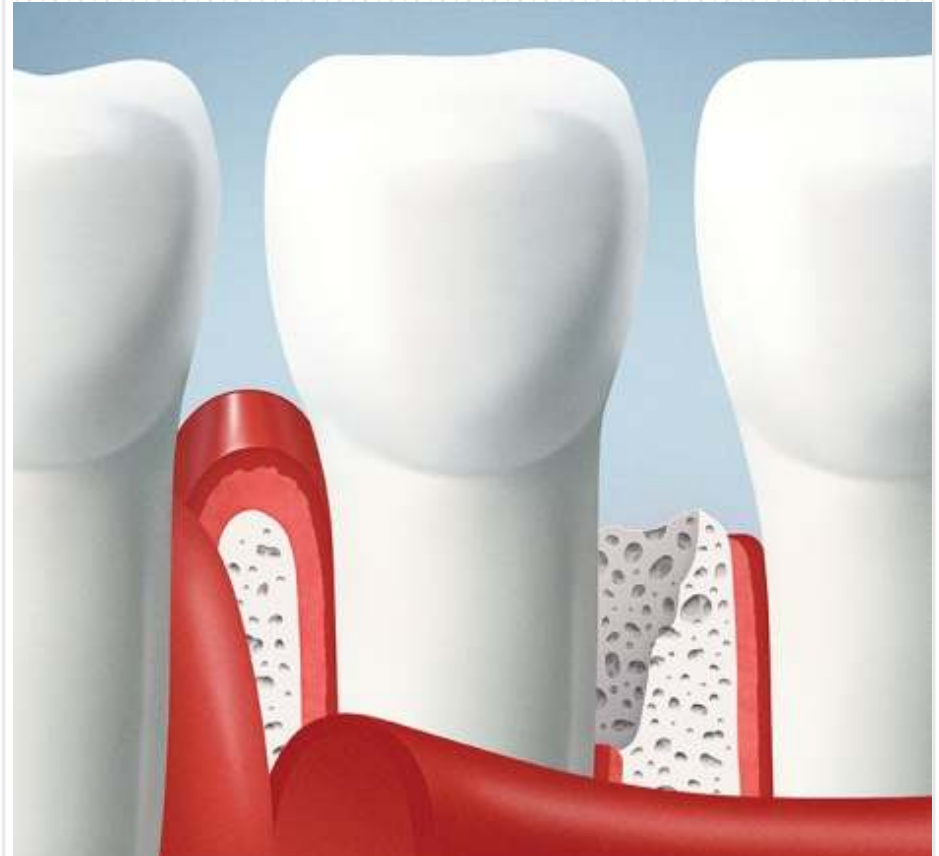
Maduravoyal, Chennai - 600 095. Tamilnadu. India.

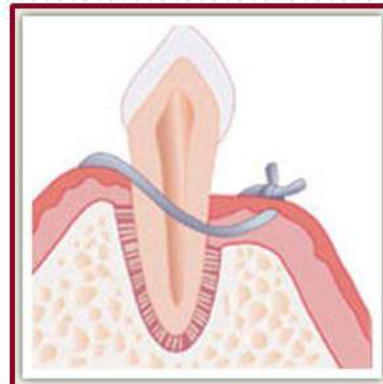
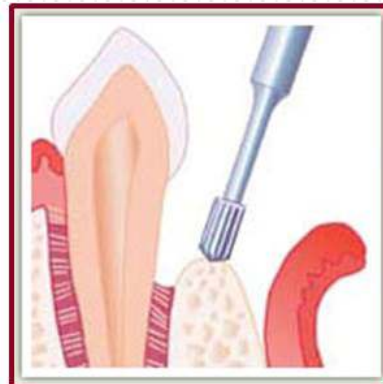
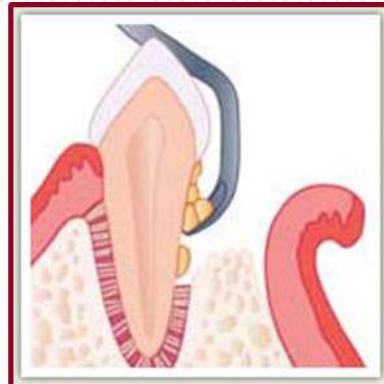
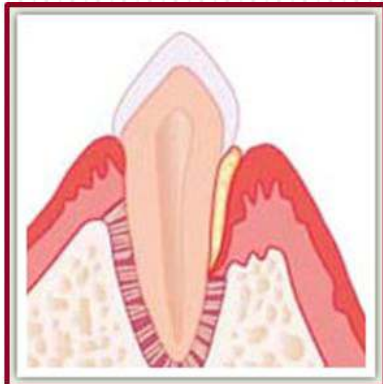
(An ISO 9001 : 2015 Certified Institution)

University with Special Autonomy Status

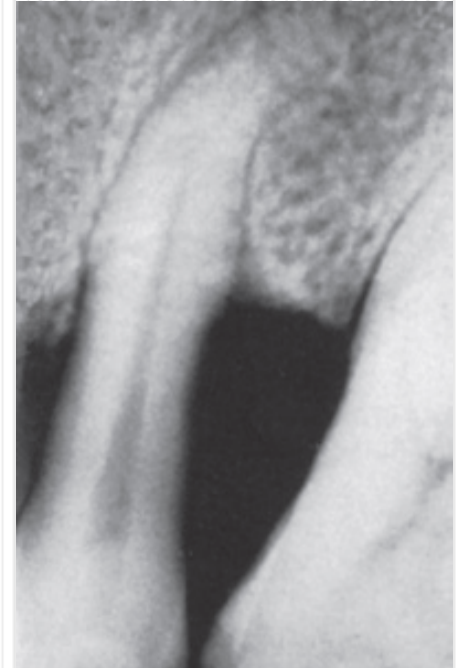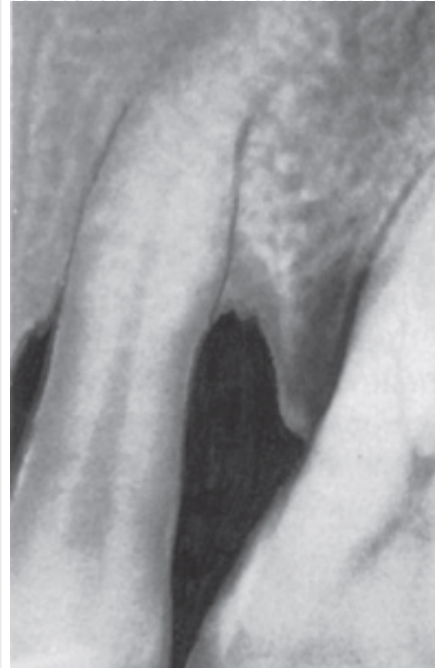
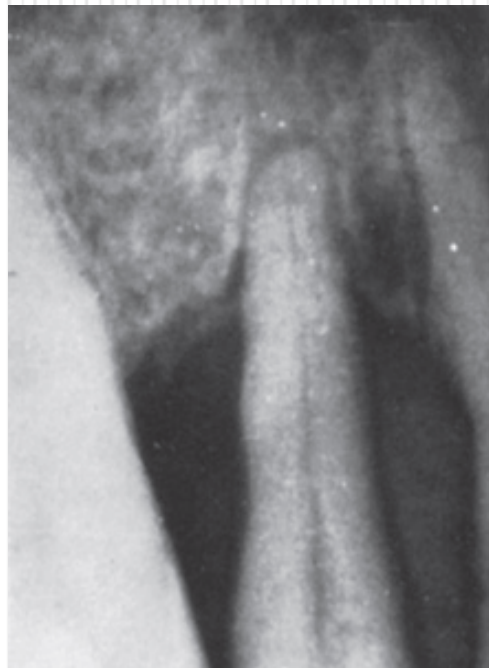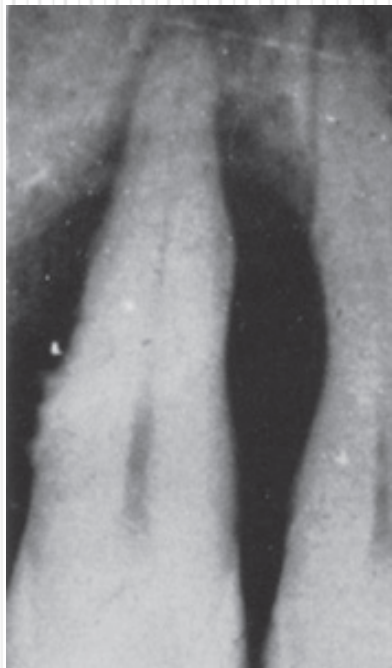



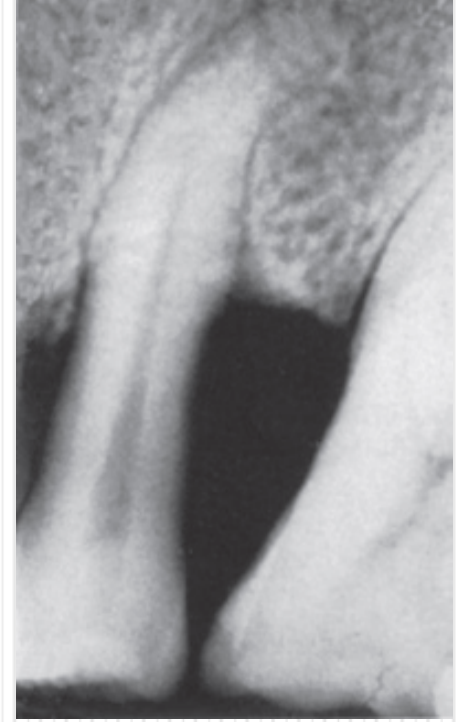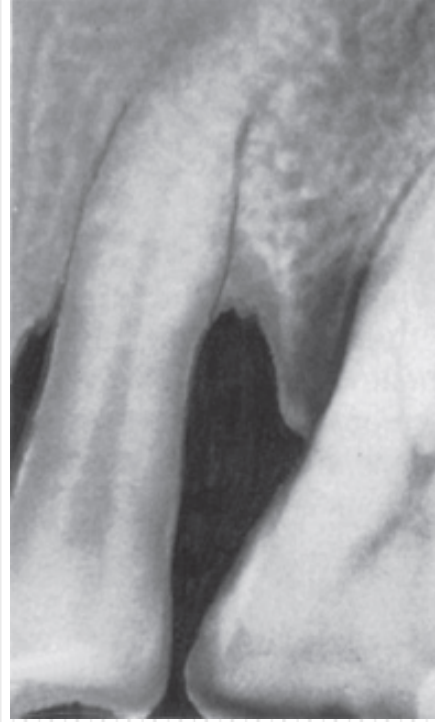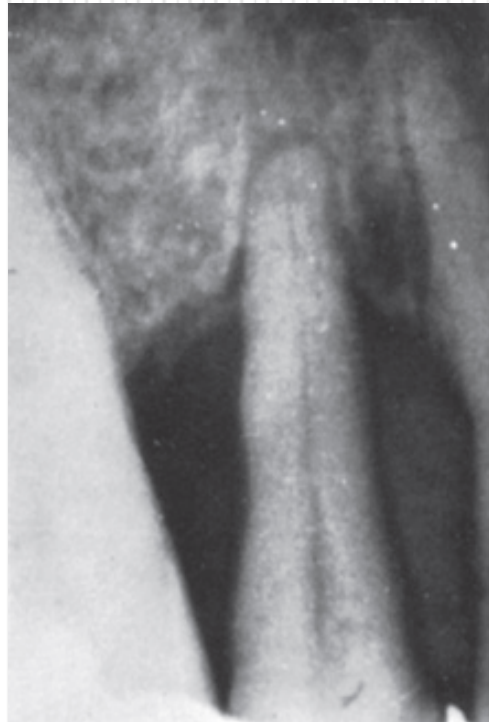
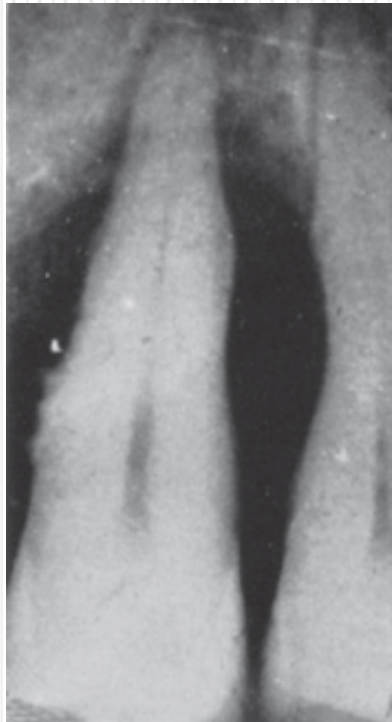
















Dr. M.G.R.
EDUCATIONAL AND RESEARCH INSTITUTE
(Deemed to be University)

Madhavoyal, Chennai - 600 095, Tamilnadu, India.




An ISO 9001 : 2013 Certified Institution



University with Special Autonomy Status


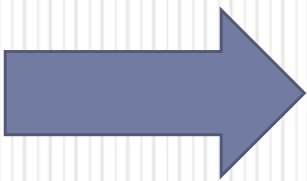
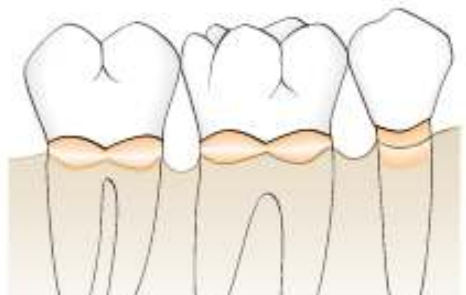
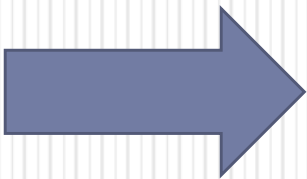
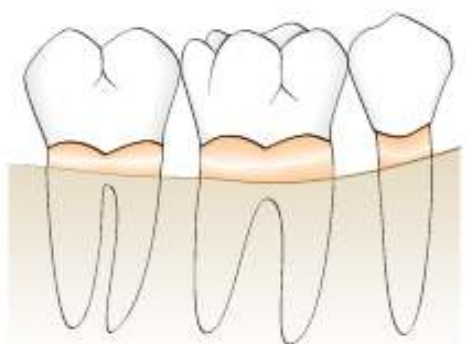
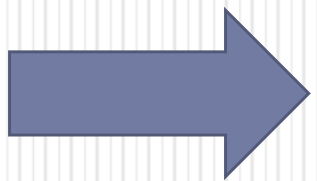
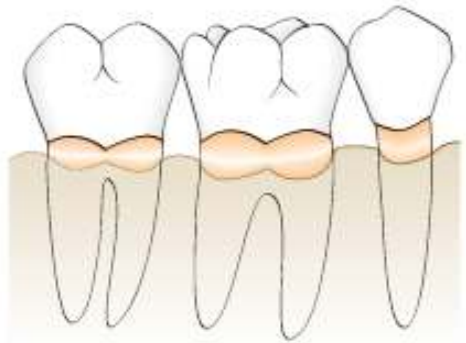



--	--	--
















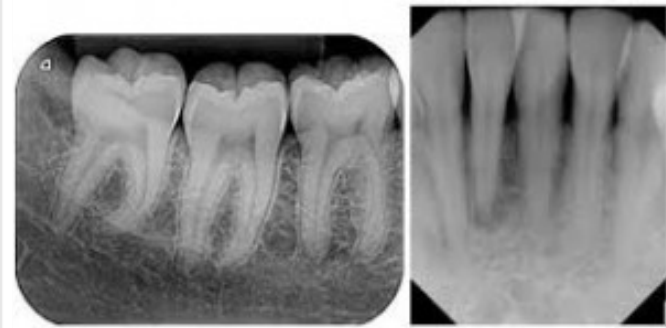
Dr. M.G.R.
EDUCATIONAL AND RESEARCH INSTITUTE
(Deemed to be University)

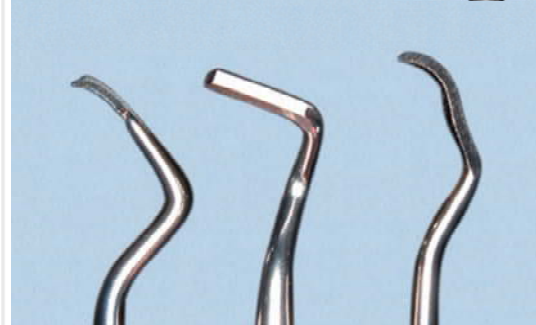
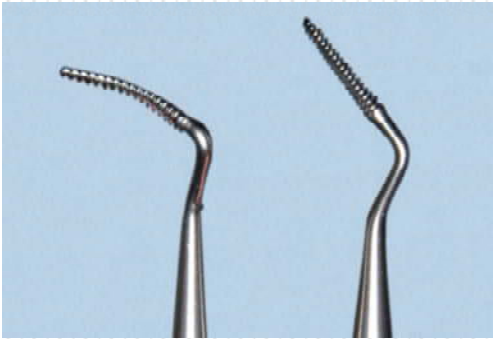
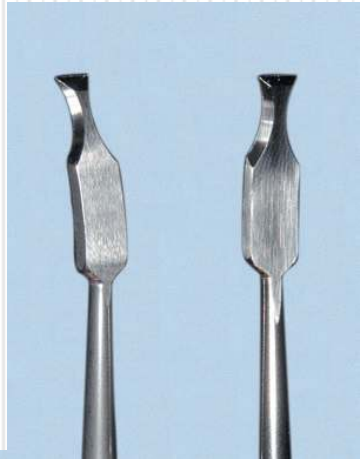
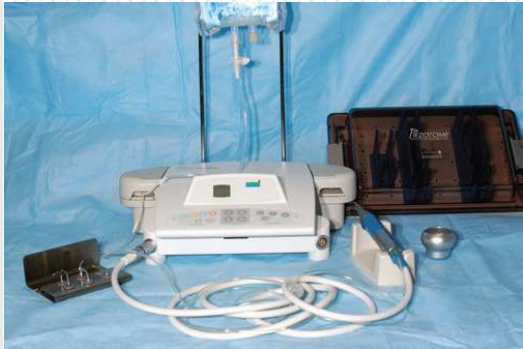Madhavoyal, Chennai - 600 095, Tamilnadu, India.


An ISO 9001 : 2015 Certified Institution

University with Special Autonomy Status










Blank rounded rectangular area for text entry.



Blank rounded rectangular area for text entry.



Blank rounded rectangular area for text entry.



Blank rectangular area for text entry.

Blank rectangular area for text entry.

Blank rectangular area for text entry.

Three large, empty, rounded rectangular boxes stacked vertically, each preceded by a blue downward-pointing chevron shape, intended for student responses.



Three empty rectangular boxes at the bottom of the page, likely for student identification or administrative use.

◆ Selection of treatment technique

1-wall

2-wall


3-wall

wide
shallow

narrow
deep

recontoured

reconsturcted

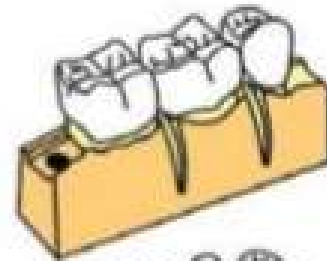


TECHNIQUE

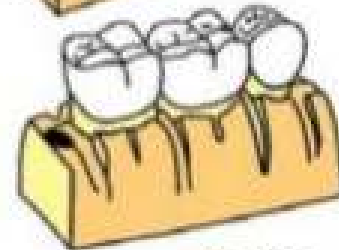
The following steps are suggested:

1. Vertical grooving.
2. Radicular blending.
3. Flattening of interproximal bone.
4. Gradualizing marginal bone.

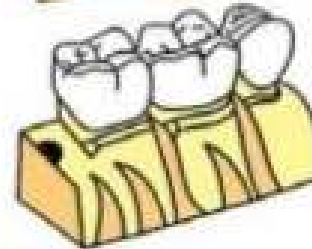
Not all the steps are necessary in each case.



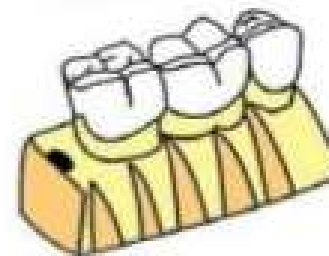
Vertical grooving



Radicular blending

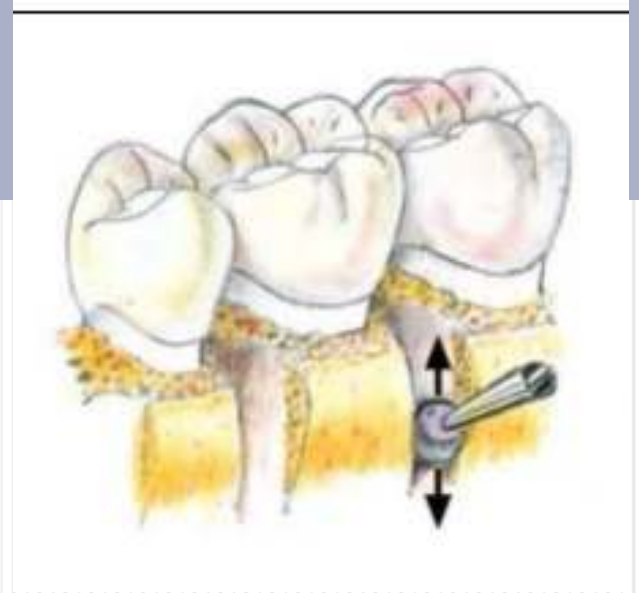

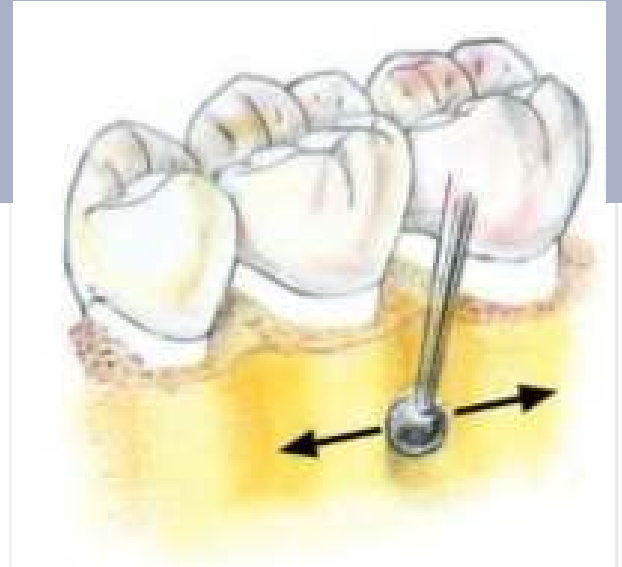
Flattening of interproximal bone

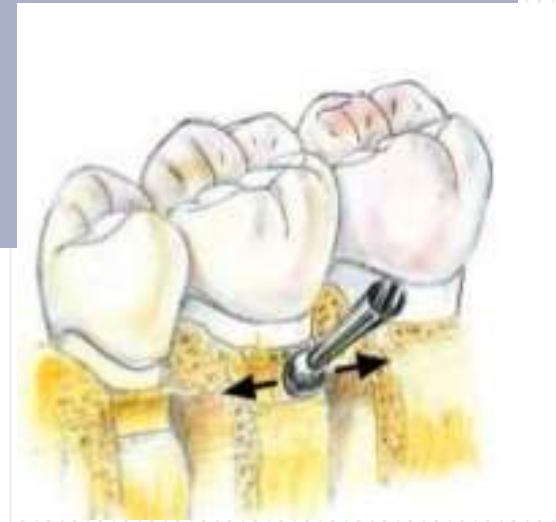







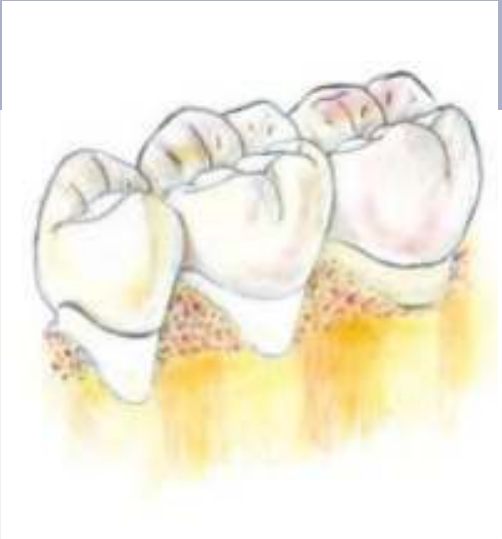
Gradualizing of marginal bone















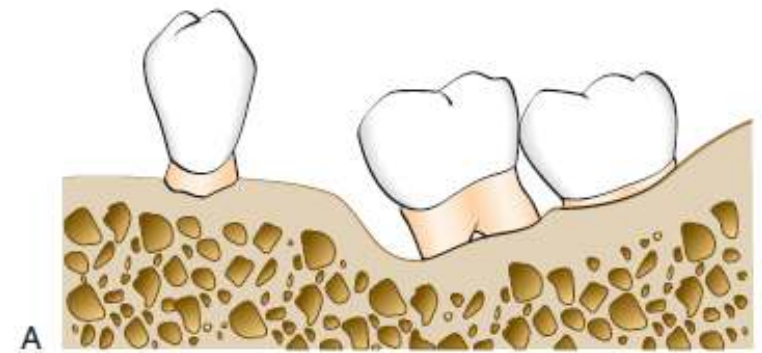


Dr. M.G.R.
EDUCATIONAL AND RESEARCH INSTITUTE
(Deemed to be University)
Madhavoyal, Chennai - 600 095, Tamilnadu, India.

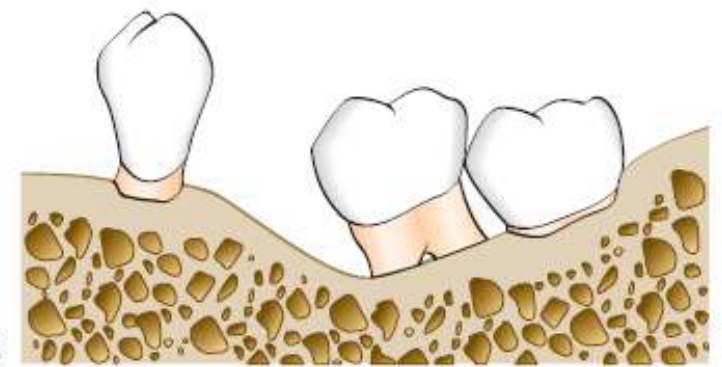


An ISO 9001 : 2013 Certified Institution
University with Special Autonomy Status

--	--	--



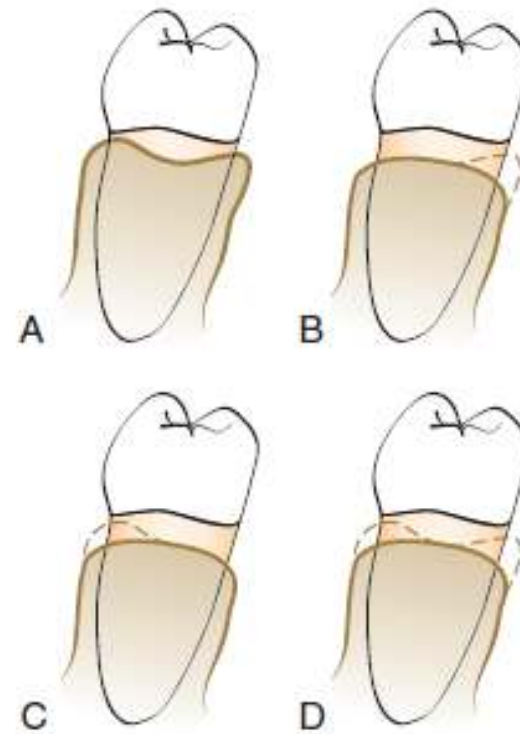
A



B

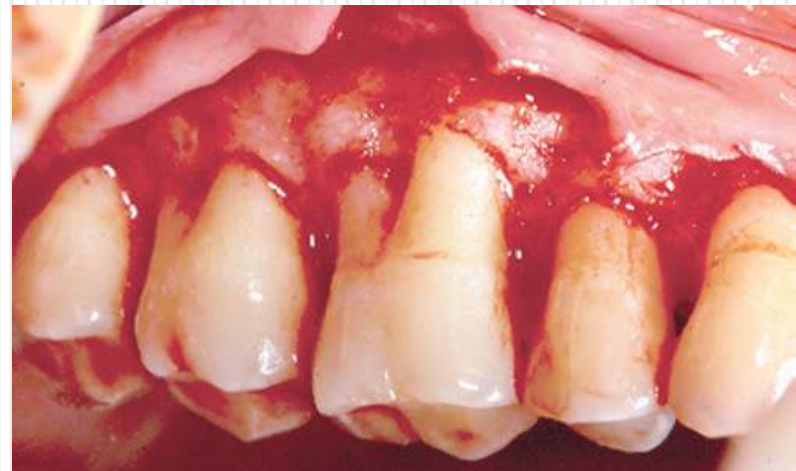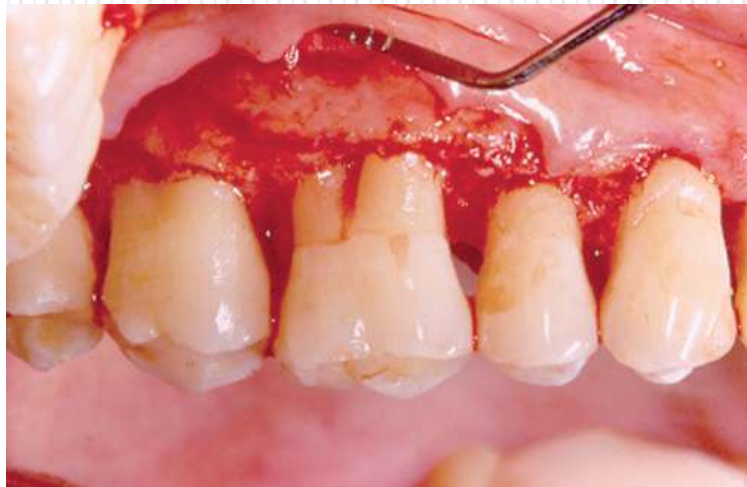
eFig. 62.8 Reduction of a one-wall angular defect. (A) Angular bone defect mesial to the tilted molar. (B) Defect reduced by "ramping" angular bone.

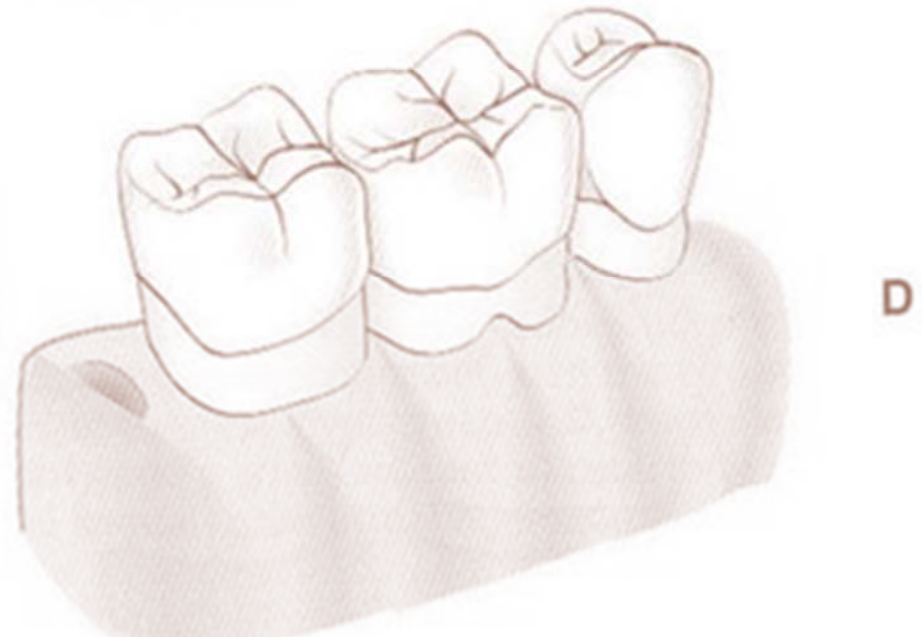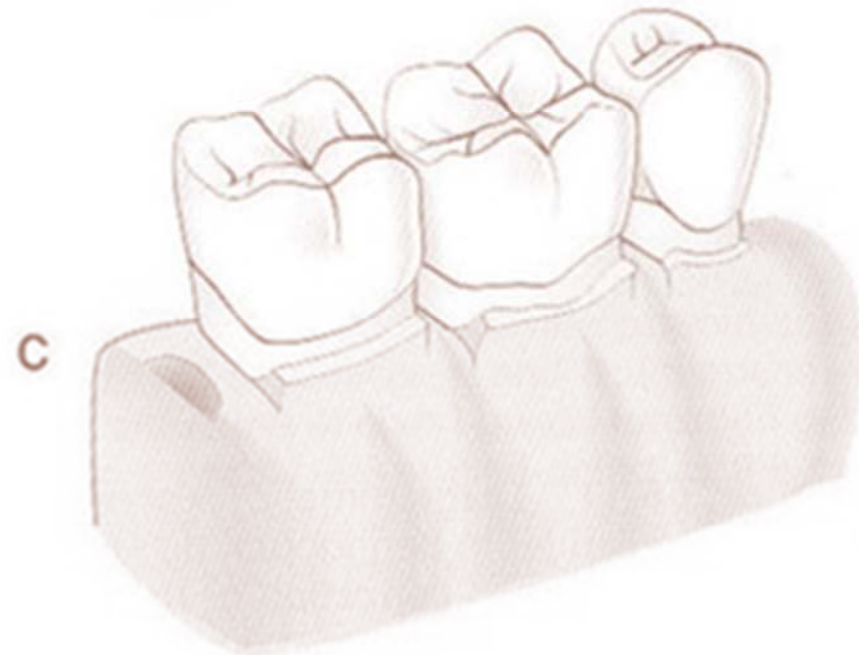
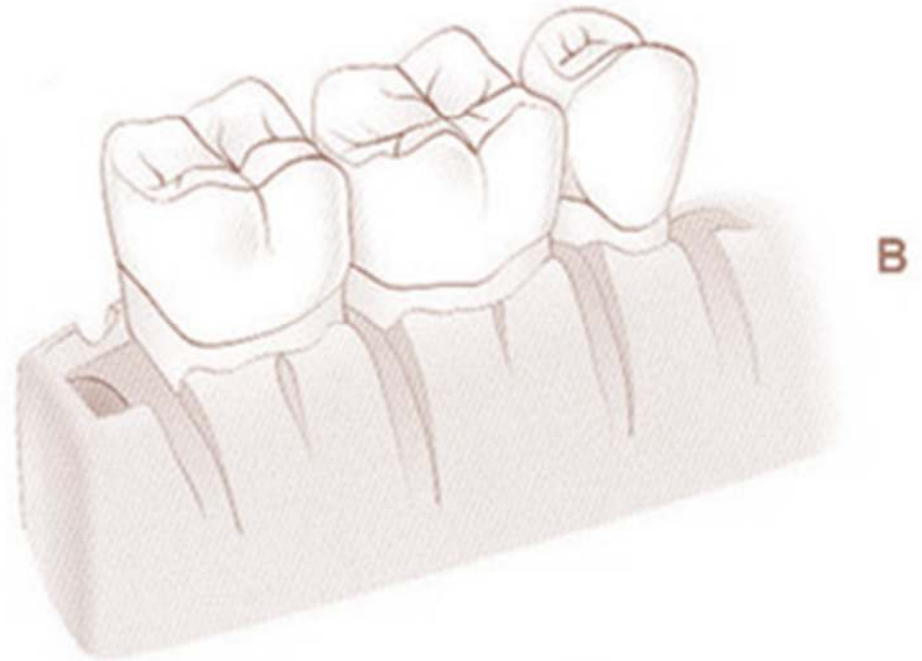
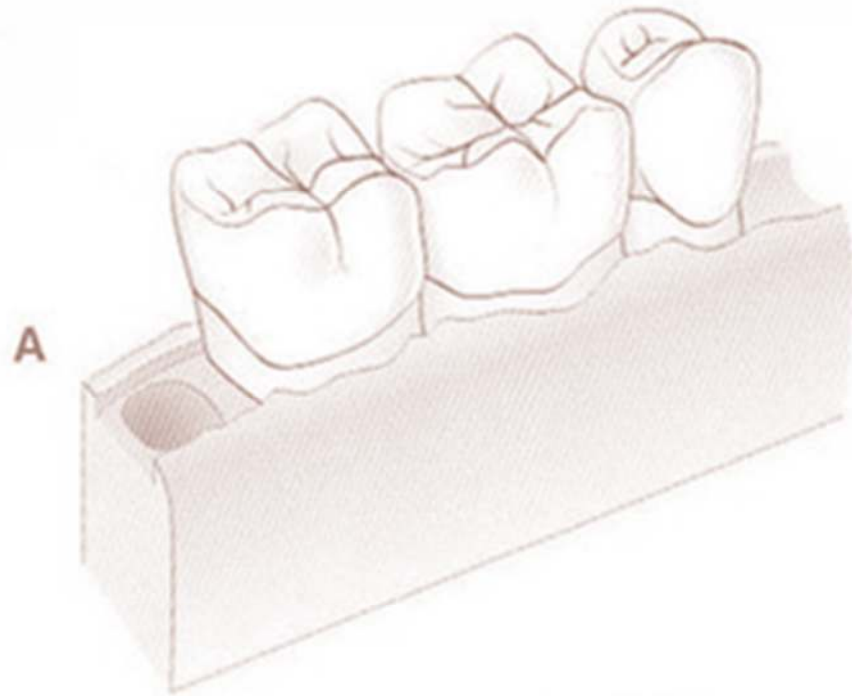




eFig. 62.9 Diagram of crater reduction patterns. (A) Preoperative bony form after flap reflection. (B) Reduction of craters to the lingual wall. (C) Reduction of craters to the facial wall. (D) Reduction of craters to both the buccal and the lingual walls.











Dr. M.G.R.
EDUCATIONAL AND RESEARCH INSTITUTE

(Deemed to be University)
Madhavoyal, Chennai - 600 095, Tamilnadu, India.

An ISO 9001 : 2013 Certified Institution

University with Special Autonomy Status

