



Dr. M.G.R

EDUCATIONAL AND RESEARCH INSTITUTE


(Deemed to be University with Graded Autonomy Status)

Accredited by NAAC with 'A' Grade | An ISO Certified Institution

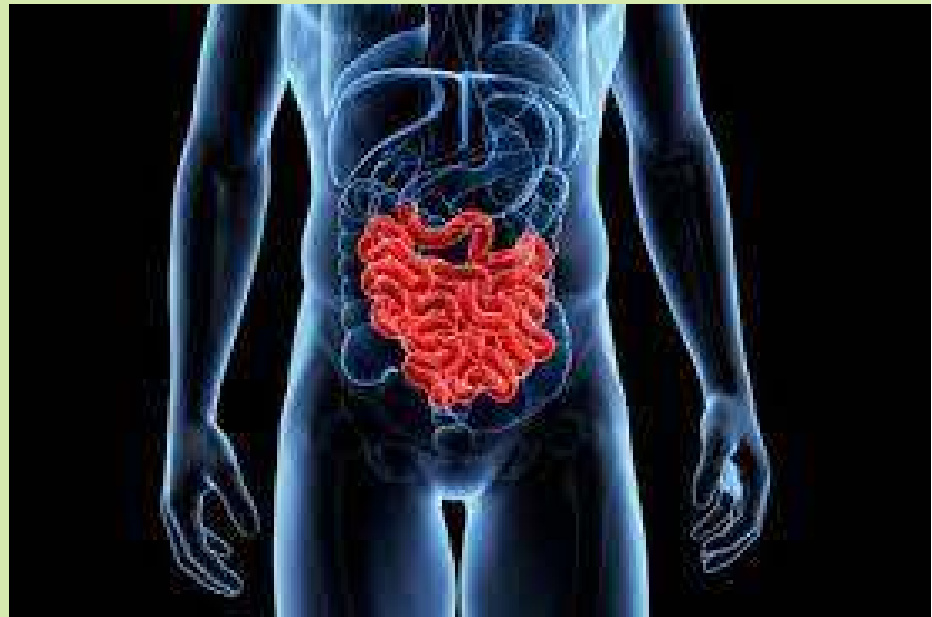Maduravoyal, Chennai - 600 095, Tamilnadu, INDIA

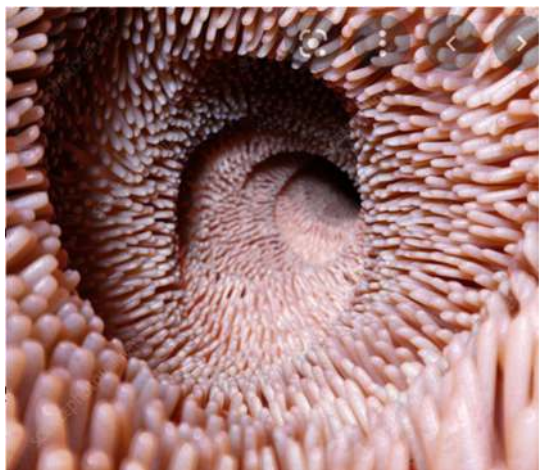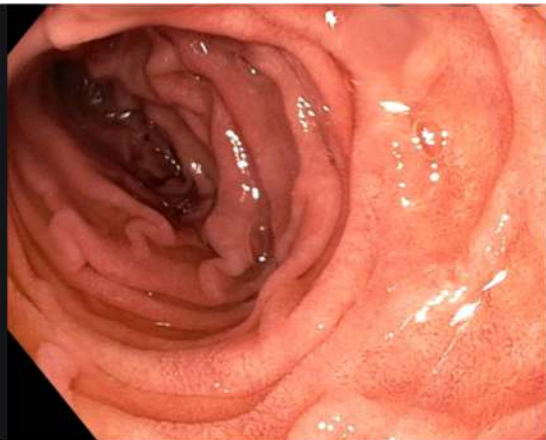Copyrights
Reserved by

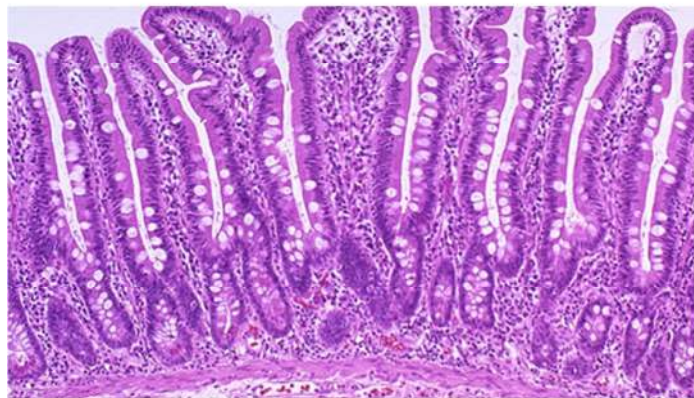




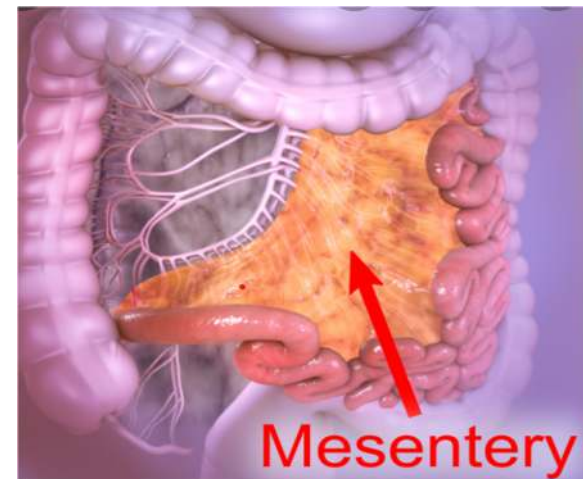
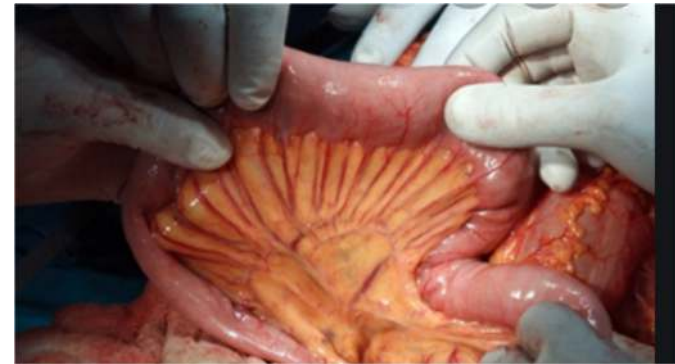-
-
-
-
-
-
-

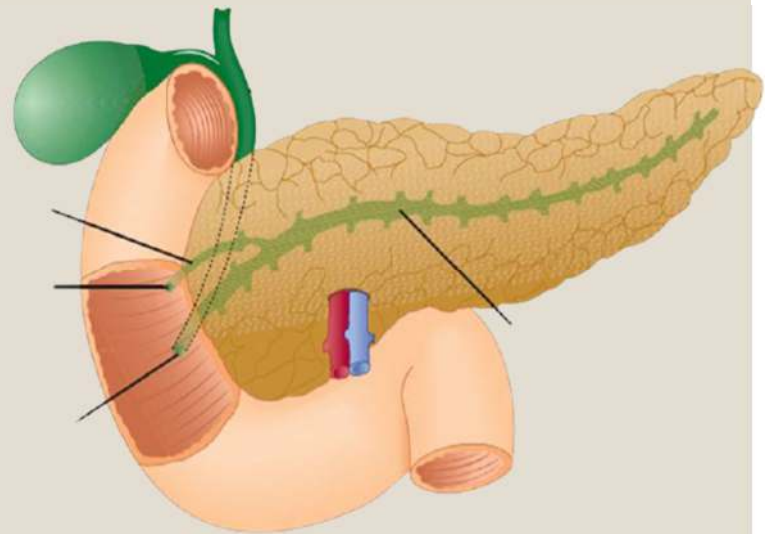

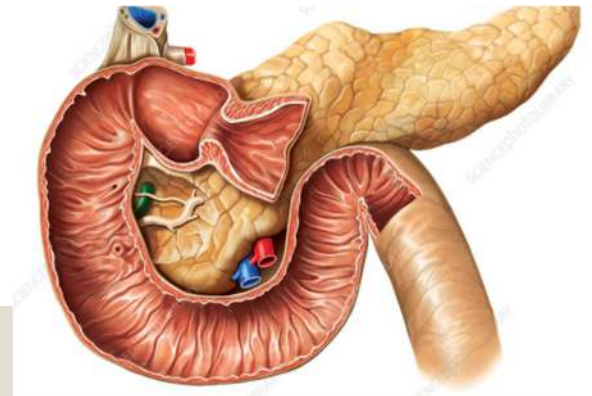


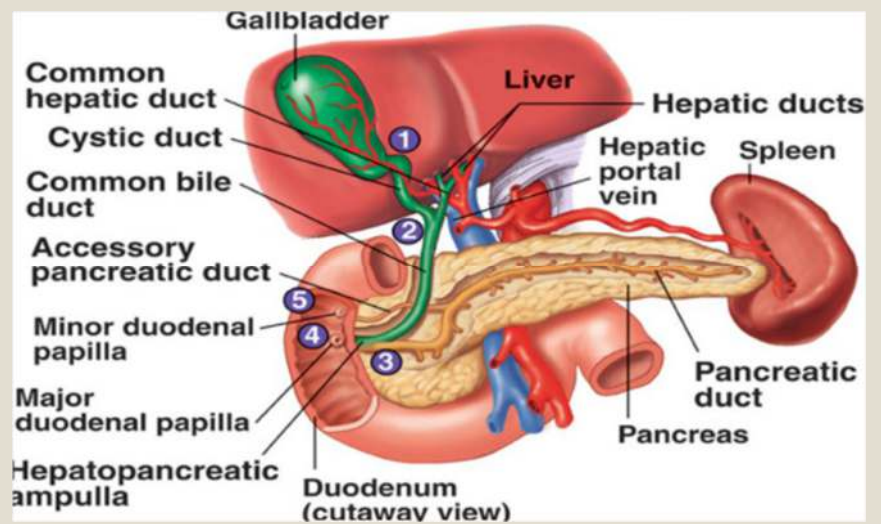


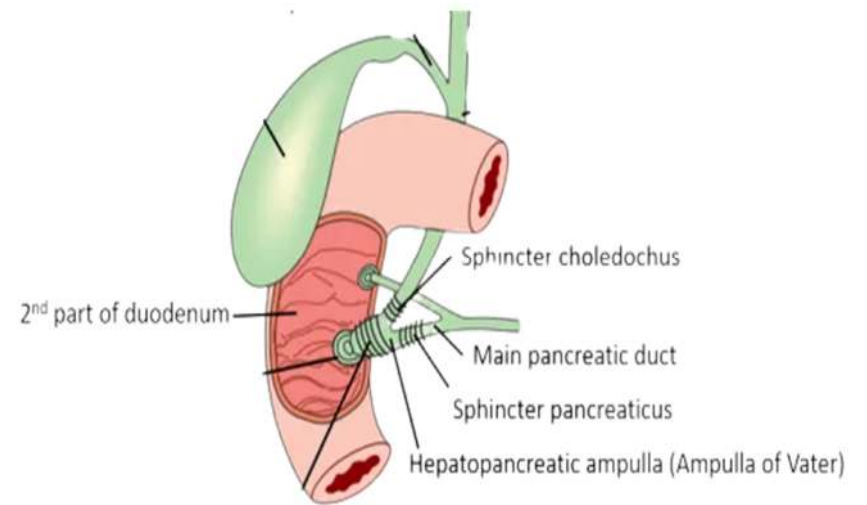


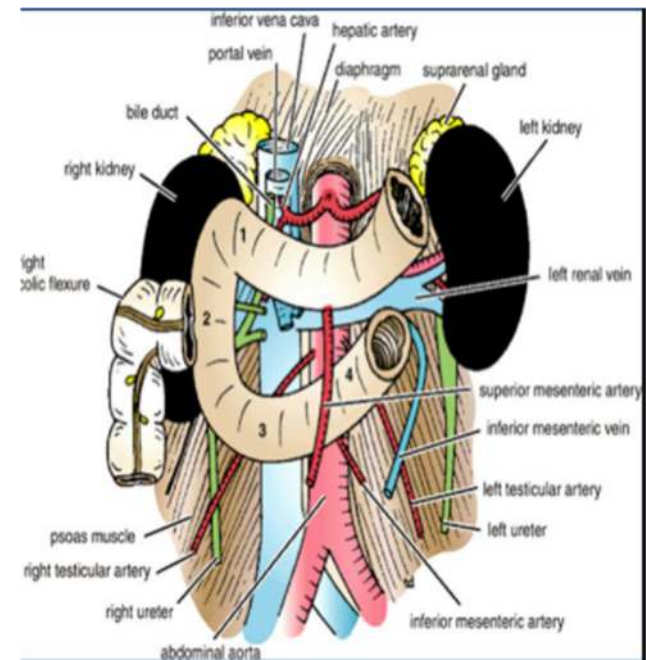
- Wall of small intestine is made of the following layers :
- a) Serosa coat
- b) Muscular coat
- c) Submucosa coat
- d) Mucosa coat
- Serosa: made of peritoneum
- Muscularis: made of smooth muscle fibers arranged in outer longitudinal & inner circular layers
- Submucosa : contains loose CT & large venous plexuses (submucosa of duodenum contains duodenal or Brunner's glands)
- Mucosa composed of a layer of epithelium, lamina propria & muscularis mucosa (Plicae circulares numerous in jejunum, Peyer's patches present in ileum)

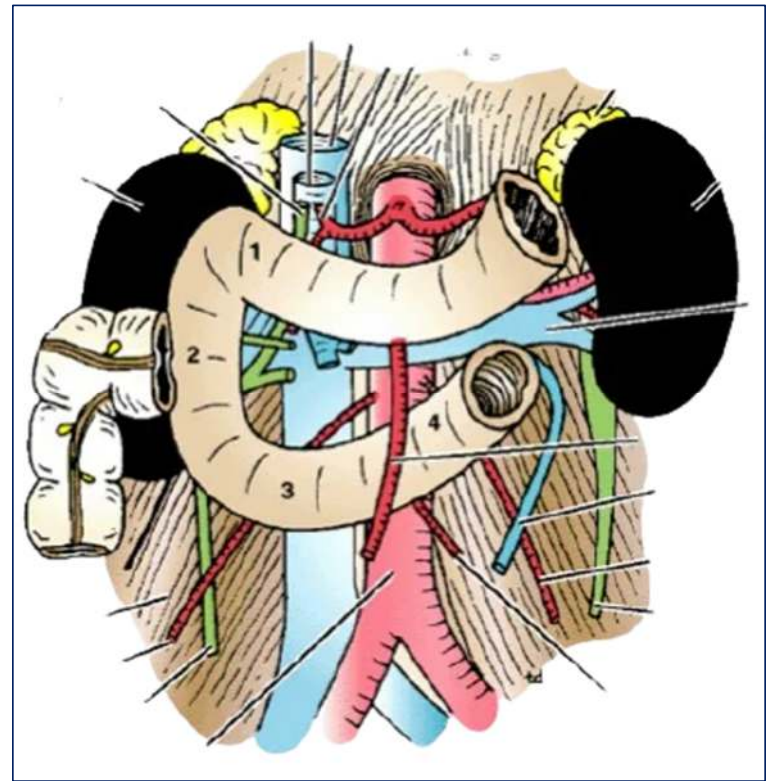


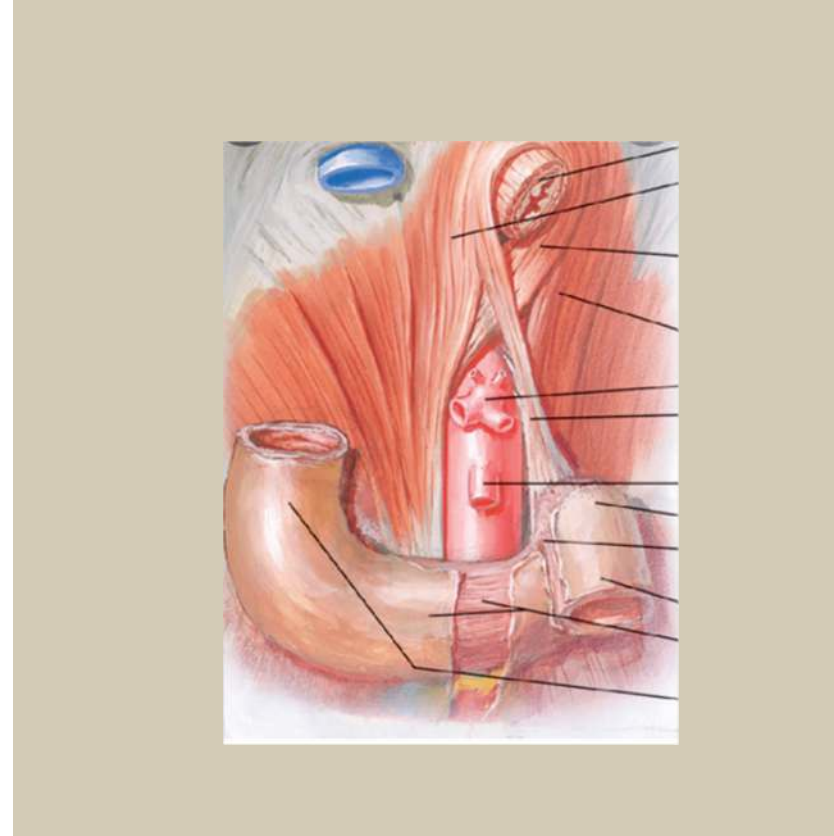



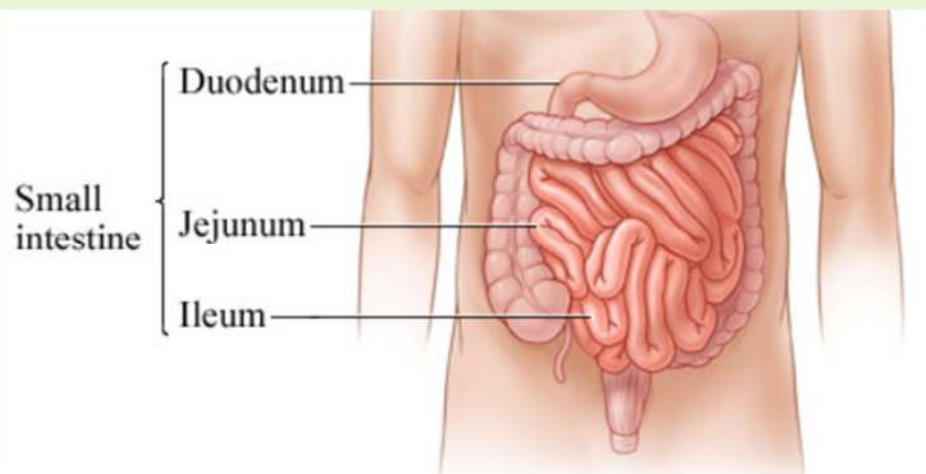






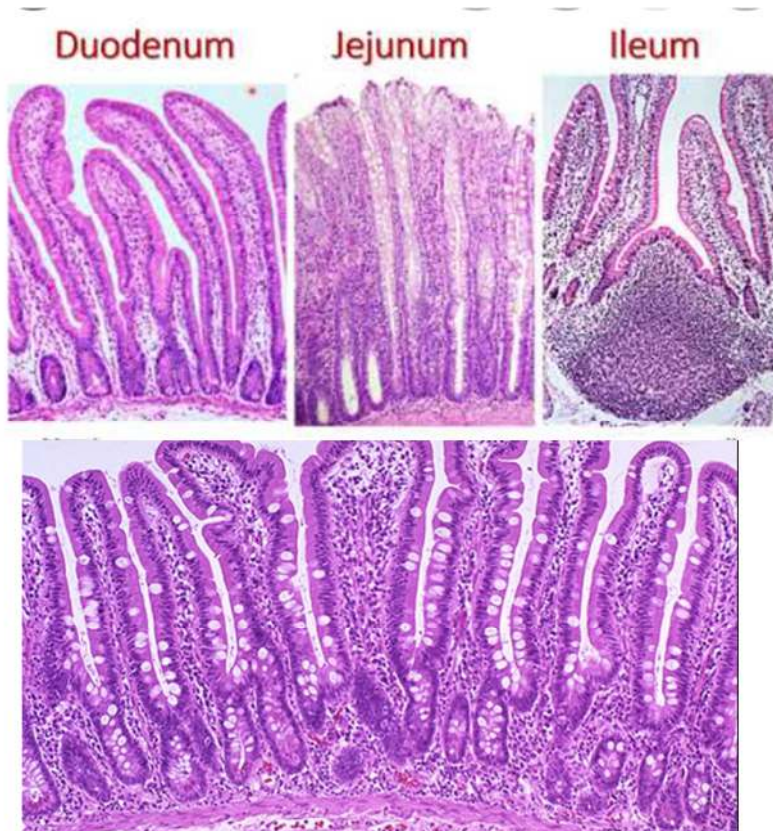









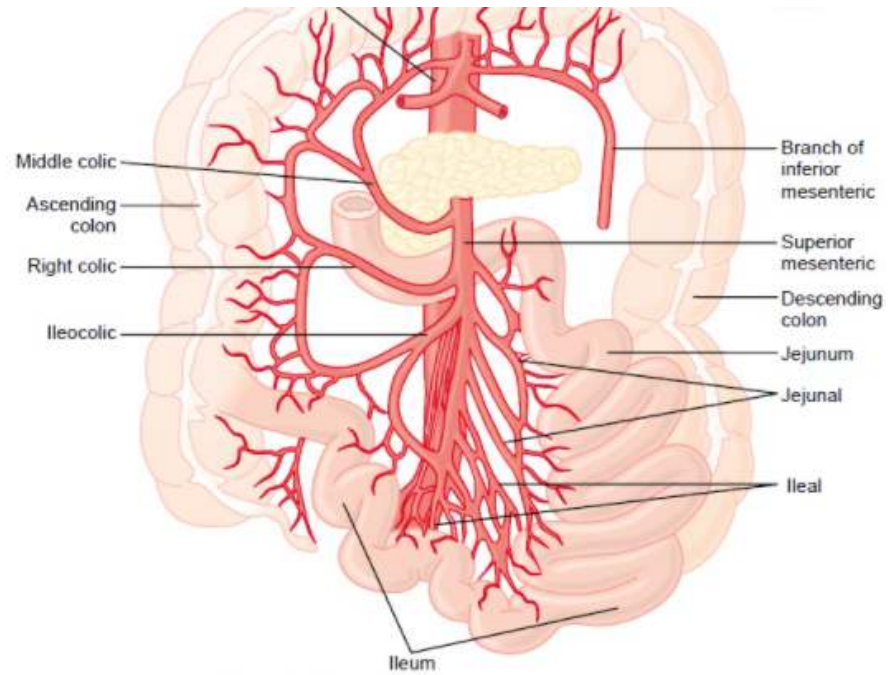
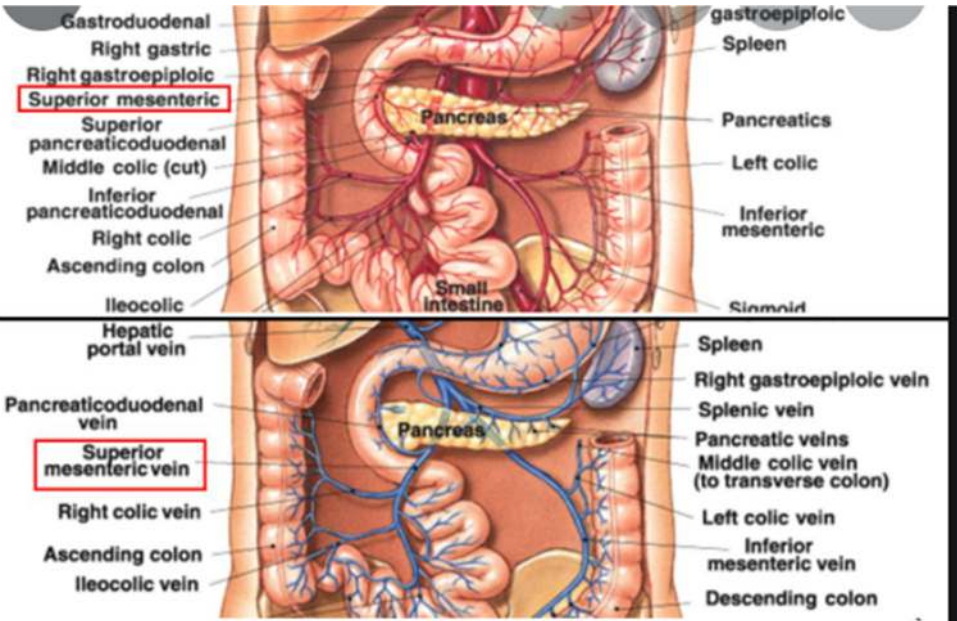


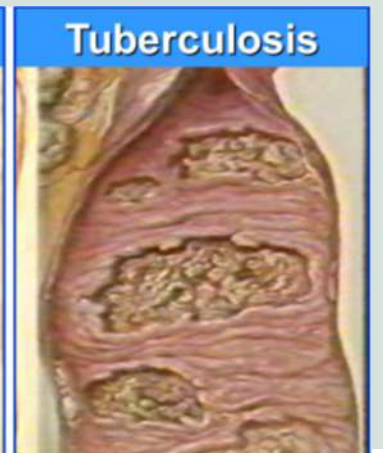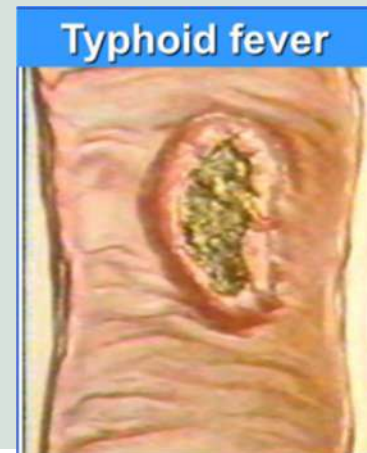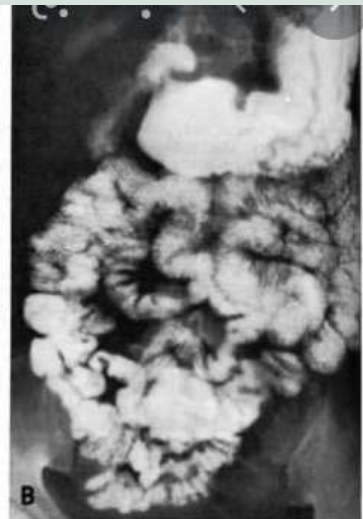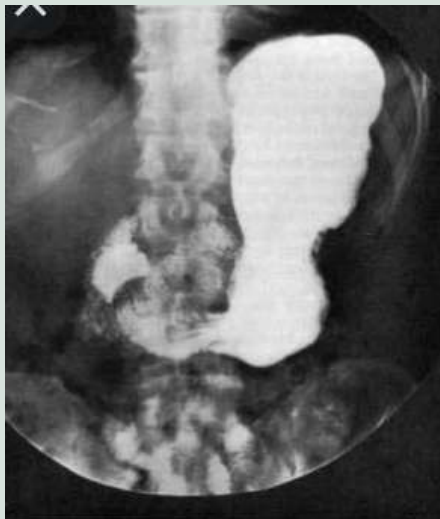
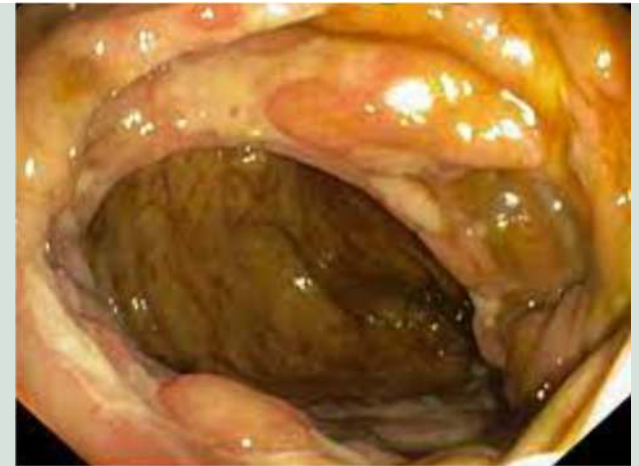
Characteristic	Jejunum	Ileum
Color	Deeper red	Paler pink
Wall	Thick & heavy	Thin & light
Vascularity	Greater	Less
Arcades	A few large loops	Many short loops
Vasa recta / arteriae rectae	Long	Short
Fat in mesentery	Less	More
Circular folds (plicae circularis)	Large, tall & closely packed (valves of Kerkring)	Low & sparse; absent in distal part
Lymphoid nodules (Peyer's patches)	Few	Many



- Wall of small intestine is made of the following layers :
- a) Serosa coat
- b) Muscular coat
- c) Submucosa coat
- d) Mucosa coat
- Serosa: made of peritoneum
- Muscularis: made of smooth muscle fibers arranged in outer longitudinal & inner circular layers
- Submucosa : contains loose CT & large venous plexuses (submucosa of duodenum contains duodenal or Brunner's glands)
- Mucosa composed of a layer of epithelium, lamina propria & muscularis mucosa (Plicae circulares numerous in jejunum, Peyer's patches present in ileum)









THANK YOU



Dr. M.G.R

EDUCATIONAL AND RESEARCH INSTITUTE

(Deemed to be University with Graded Autonomy Status)

Accredited by NAAC with 'A' Grade | An ISO Certified Institution

Maduravoyal, Chennai - 600 095, Tamilnadu, INDIA